

La **DIAGNOSTICA** **EMATOPATOLOGICA** nell'ERA della **MEDICINA** di **PRECISIONE**

Clinical case

Dr.ssa Silvia Tozzini

Azienda USL Toscana Centro - SOC Anatomia Patologica Pistoia

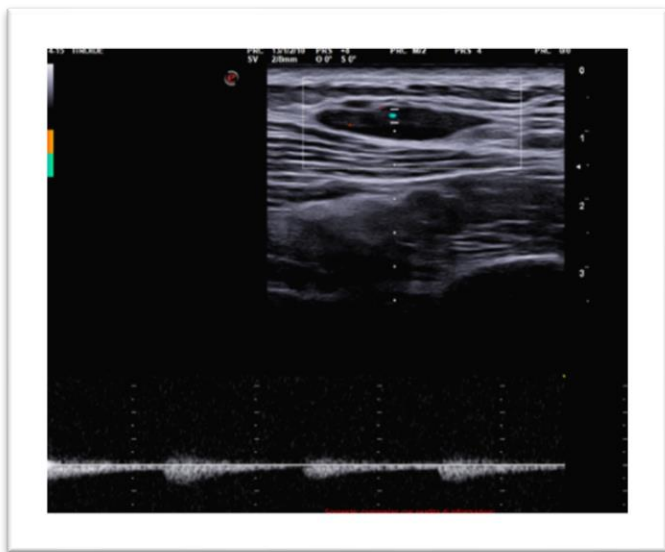
Male, 67 years old.

October 2025: appearance of a centimeter - long subcutaneous swelling in the right periscapular region.

Medical History

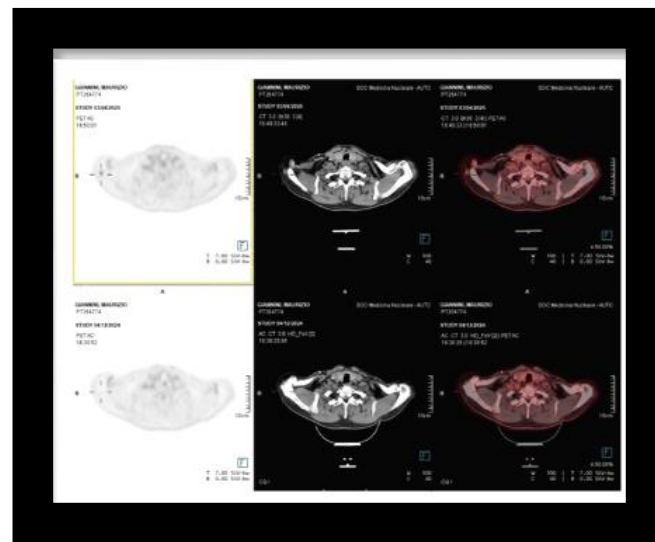
- ✓ 2015: colorectal adenocarcinoma (G3/high grade) with lymph node and liver metastases (pT2 N1b M1a).
- ✓ 2022: massive ileal involvement by peripheral B-cell lymphoma, centrofollicular, Grade 3A.
- ✓ 2024: retroauricular soft-tissue localization of peripheral B-cell lymphoma, centrofollicular.

Ultrasound and PET were performed.



Ultrasound

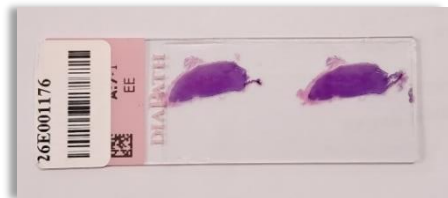A 25x10x5 mm
hypoechoic subcutaneous lesion with rather
clear margins.



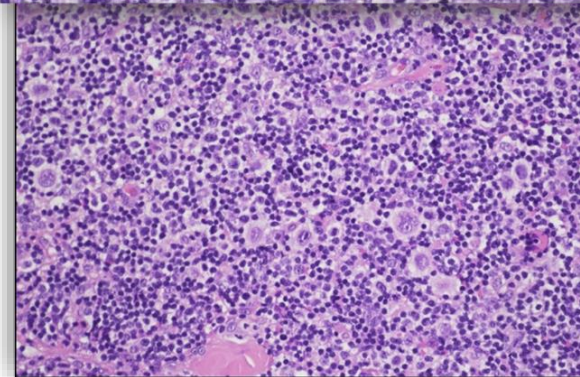
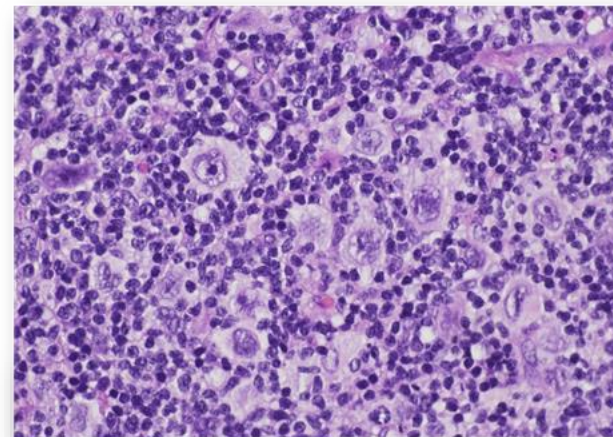
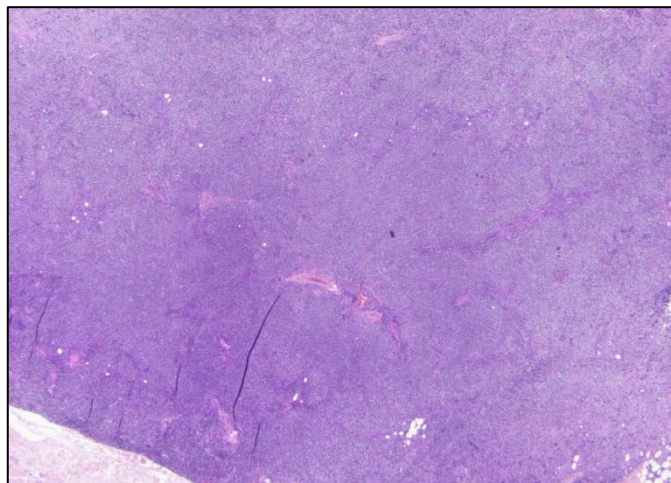
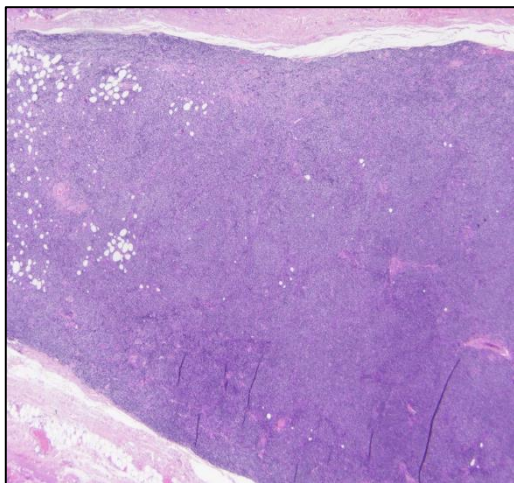
PET

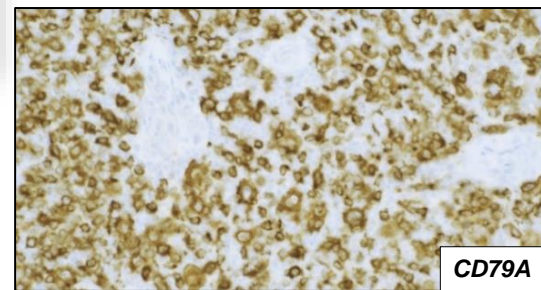
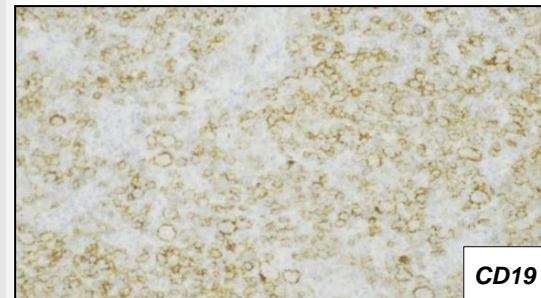
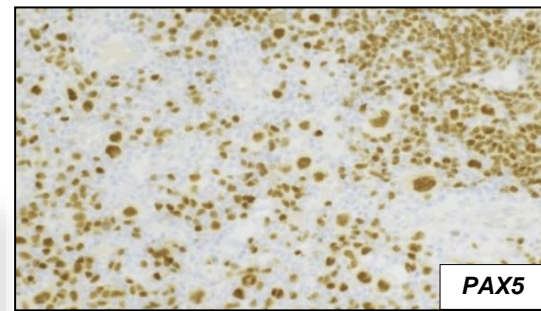
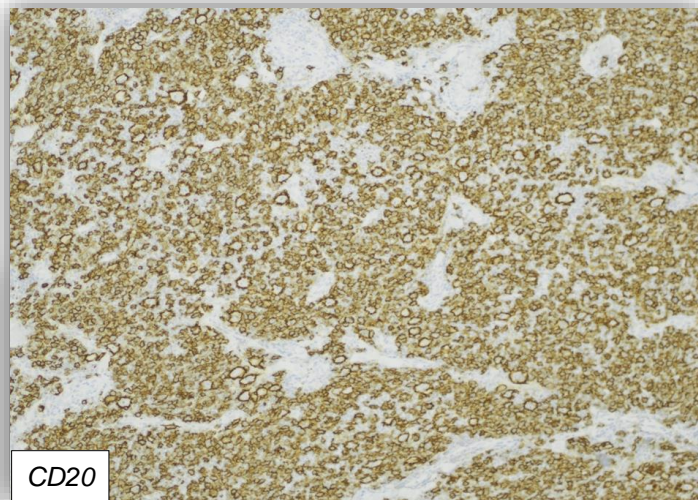
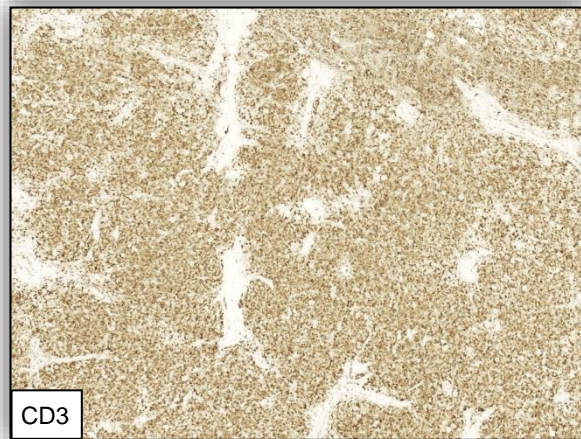
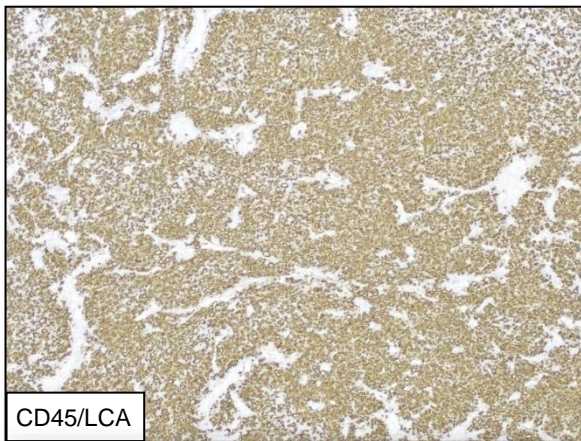
Area of hypermetabolism in the right
periscapular subcutaneous region.

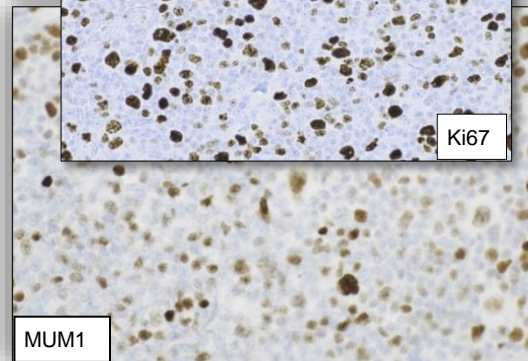
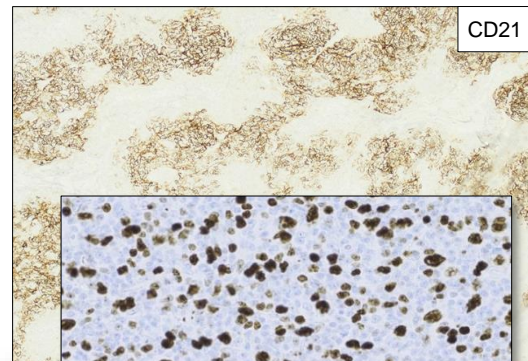
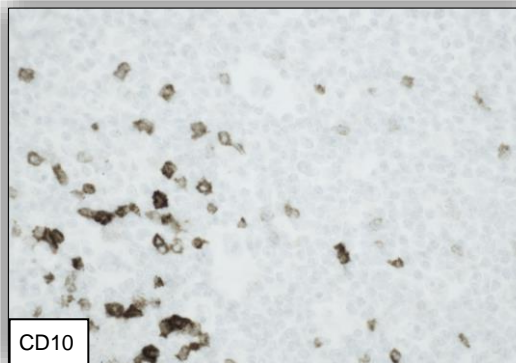
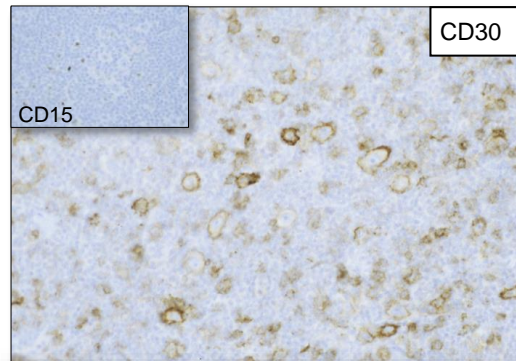
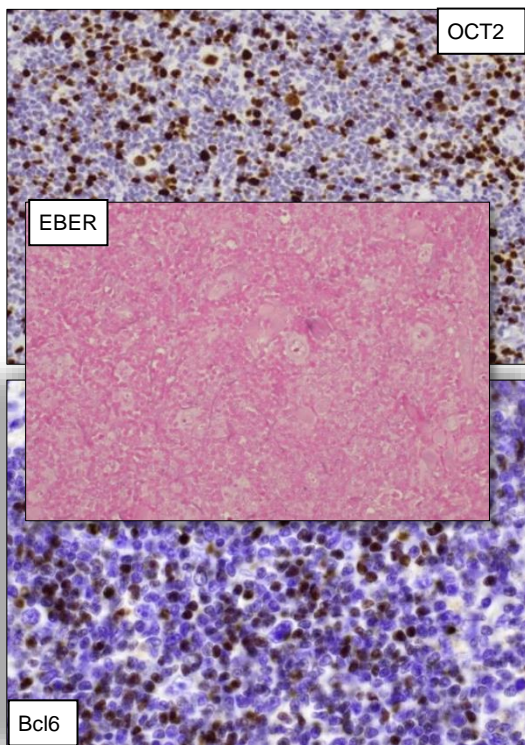
Surgical excision was performed



Macroscopic examination
solid, whitish, oval lesion, measuring 2 cm in length.

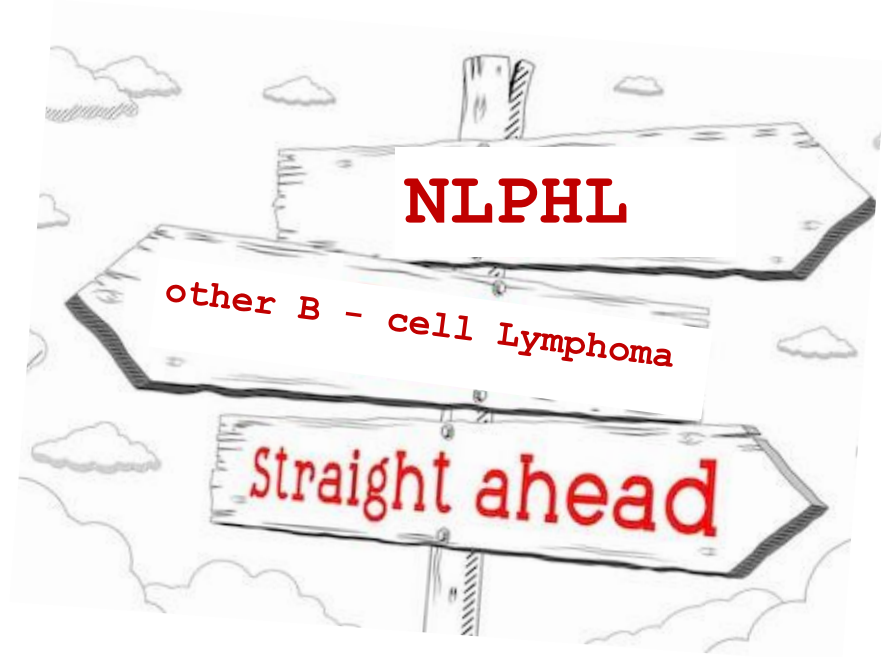




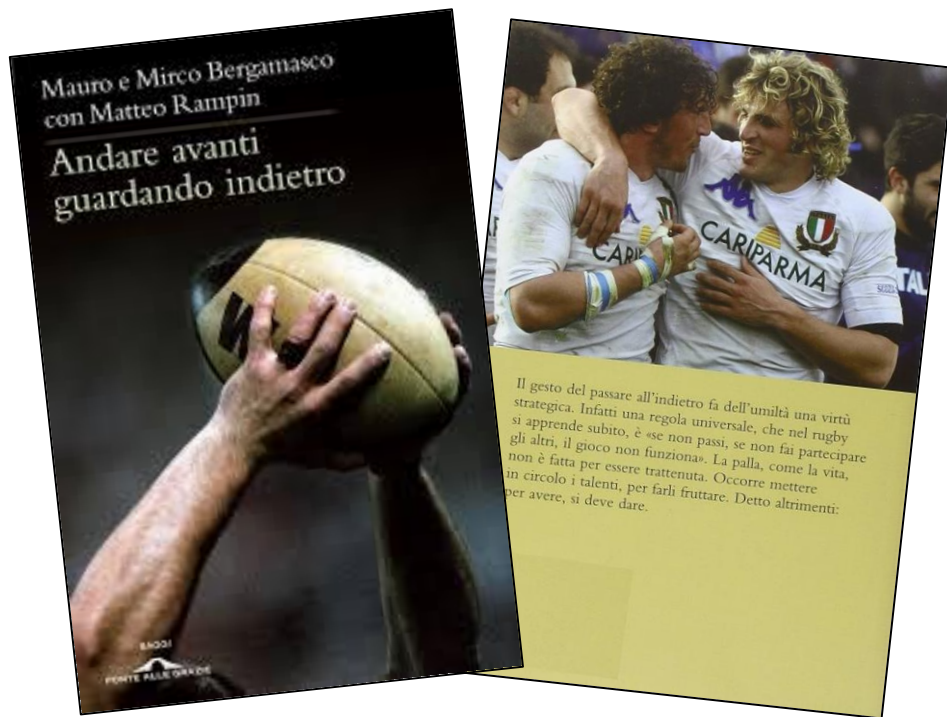

Main histologic features

- Plurinodular / serpiginous architecture;
- Widespread B – cell reactivity with abundant T lymphocytes.
- LP - like cells (CD20+, CD79A+, CD19+, PAX5+, Bcl6-, CD10-, MUM1+, OCT2+, CD30-/+, CD15-, EBV-).



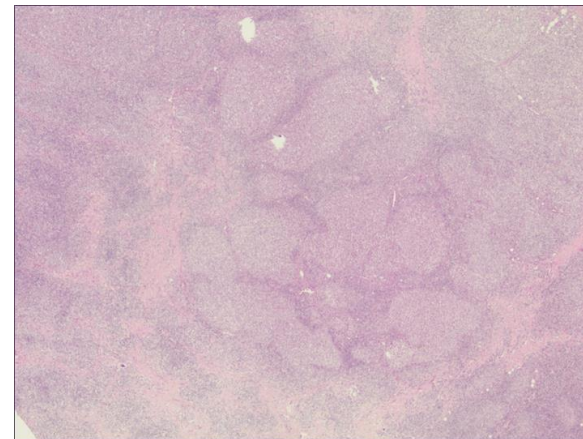
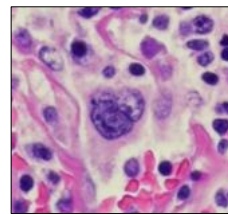
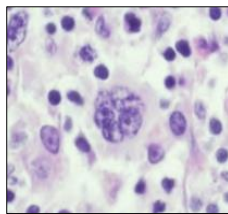
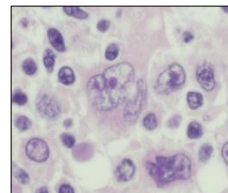
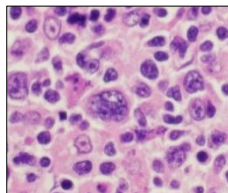
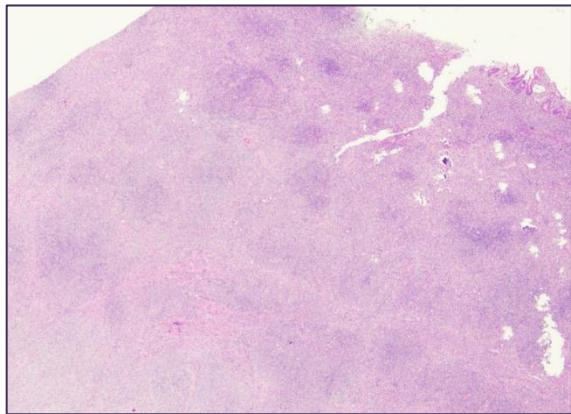
It's a B-cell lymphoma!



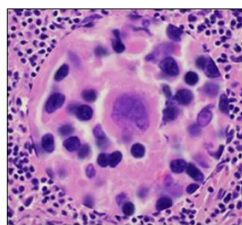
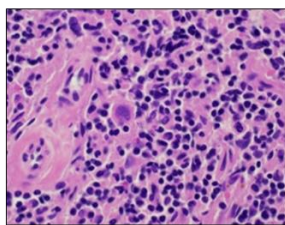
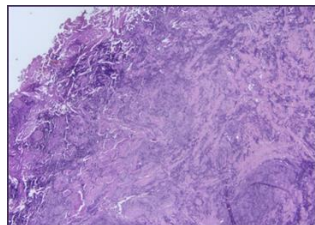
Just like in Rugby...

... let's move forward, while
looking back to the previous
lymphoma!

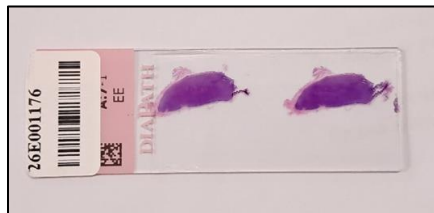Ileum



Retroauricular soft tissue



- *CD20+*, *CD3/CD5-*, *CD10-*, *Bcl6-*, *Bcl2+*
- *t(14; 18) - positive FL*
- *Pop-corn cells present*



BCL2-R positive

FL with LPHL - like features



Opinion

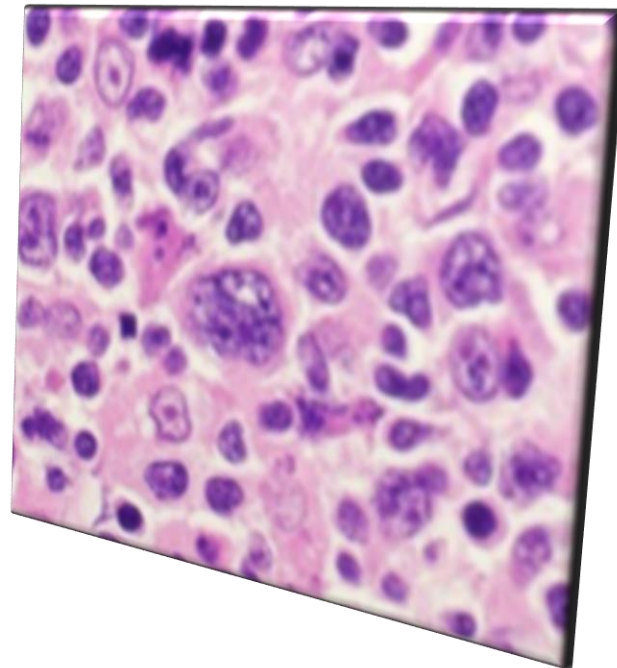
Nodular Lymphocyte-Predominant Hodgkin Lymphoma: A Special Type of (Follicular) B-Cell Lymphoma?


Antonino Carbone ^{1,*} and Annunziata Gloghini ²

- ¹ Centro di Riferimento Oncologico, Istituto di Ricovero e Cura a Carattere Scientifico, National Cancer Institute, 33081 Aviano, Italy
 - ² Department of Advanced Pathology, Fondazione IRCCS Istituto Nazionale dei Tumori, 20133 Milan, Italy; annunziata.gloghini@istitutotumori.mi.it
- * Correspondence: acarbone@cro.it; Tel: +39-0434-659085

Abstract: The clinicopathologic spectrum of nodular lymphocyte-predominant Hodgkin lymphoma, now termed “nodular lymphocyte-predominant B-cell lymphoma” (NLPBCL), may include incipient, typical and transformed forms. On the basis of its clinicopathologic spectrum, NLPBCL is very similar to follicular lymphoma not associated with *BCL2* translocation. In addition, NLPBCL, based on biopathologic features (gene profiling signature, and phenotypic and morphotypic characteristics), is a germinal center-derived B-cell neoplasm; therefore, it could be included in the follicular lymphoma group of non-Hodgkin lymphoma.

Keywords: Hodgkin lymphoma; B-cell lymphoma; follicular lymphoma; in situ neoplasia; transformed lymphoma





Grazie per l'attenzione.